

# Hemisection: One Large Step Toward Management of Congenitally Missing Lower Second Premolars

William Northway, DDS, MS<sup>a</sup>

**Abstract:** When the primary molar cannot be retained in cases of agenesis of the lower second premolar (CML5), there is the possibility of alveolar atrophy, and space closure might have a negative impact on facial fullness. Bearing these in mind, the removal of the distal half of the second primary molar might allow closure in stages. Subsequent removal of the mesial half can be followed by space closure. Using this hemisection approach, space closure can be continued with ease improving treatment results. In order to test the amount of anchorage loss resulting from this approach, the pitchfork analysis was used to compare a group of 23 consecutively treated patients, each treated by hemisection, with two groups of 30 patients, each of whom was treated with the extraction of four premolars. One group had four first premolars removed and the second group had second premolars removed. In order to obtain an untreated "control," these were further compared with the difference between the Bolton templates at ages nine and twelve. The CML5 group was divided into those which had upper teeth extracted in order to facilitate the correction and those who were treated without extraction in the upper. The hemisection groups showed statistically significant diminished distal movement of the upper incisor as well as the upper and lower lip. Lower molar protraction and molar relation was significantly increased. The process facilitates the keeping of upper premolars, which further enhances the facial fullness. (*Angle Orthod* 2004;74:790–797.)

**Key Words:** Pitchfork analysis; Extraction therapy; Facial fullness; Alveolar atrophy

## INTRODUCTION

Missing teeth present a myriad of treatment options ranging from keeping the primary tooth to placing implants. The treatment decision can be easy if there is crowding or significant protrusion or if the primary tooth is ankylosed or otherwise compromised. However, what if none of these factors present? Are you prepared to take your chances with keeping a primary molar that might eventually resorb its roots? If you make the decision to treat the case by extracting the primary molar, are you prepared to accept the diminished contour of the alveolar ridge mesial to the molar after the closure of a 10-mm extraction site? What about the anchorage consequences in terms of support for the soft tissue profile? This study examines the effect of hemisecting the second primary molar in the treatment of congenitally missing lower sec-

ond premolars (CML5), a step that has the potential to greatly facilitate space closure.

In the 1970s, Garn<sup>1</sup> developed theories of genetic control mechanisms, which work along gradients involving reductions in tooth number, tooth size, rates of formation, and formation sequence. He argued that when M3 is congenitally missing, other teeth tend to be missing, generally the more distal in each morphological class, ie, most likely P2, M2, I2. Peck et al<sup>2</sup> correlated agenesis of third molars and lower second premolars with palatally displaced canines and peg-shaped laterals. Baccetti<sup>3</sup> corroborated these findings and added submerged primary molars and enamel hypoplasia to the list of correlates.

Subsequently, Baccetti divided anomaly types into two categories. He termed the first positional anomalies, represented by failures in eruption of first and second molars (which he correlated with palatally displaced maxillary canines), infraocclusion of primary molars and rotated maxillary lateral incisors. He described a second form, developmental anomalies, which he related to alveolar bone or periodontal ligament metabolism. These are represented by aplasia of second premolars, reduced size of maxillary lateral incisors, and enamel hypoplasia.<sup>4</sup>

Nodal et al<sup>5</sup> and Øgaard and Krogstad<sup>6</sup> demonstrated a

<sup>a</sup> Private Practice, Traverse City, MI.

Corresponding author: William Northway, DDS, MS, 12776 S. West Bay Shore Drive, Traverse City, MI 49684 (e-mail: northway@umich.edu).

Accepted: December 2003. Submitted: September 2003.

© 2004 by The EH Angle Education and Research Foundation, Inc.

flattening effect on facial features when multiple teeth are missing, especially when measured by FMA, LFH, interincisal angle, lower incisor to A-Po, lower incisor to MP, and LL-EP. Slavkin<sup>7</sup> has divided the number of missing teeth into categories and defined hypodontia as the absence of one to six teeth, oligodontia as more than six teeth missing, and reserved the term anodontia for the total absence of teeth. He reported the incidence of agenesis as between 1.9% and 6.9%, depending upon the sample tested (as high as 20% if third molars are included). The incidence of agenesis of lower second premolars has been shown to range between 3% and 4.4%.<sup>8,9</sup>

To date, the only reference in the literature to hemisection of the primary molar appears in part 4 of the book by Dr. Frans van der Linden in his series, *Problems and Procedures in Dentofacial Orthopedics*.<sup>10</sup>

If, as reported in the literature, cases that present congenitally missing lower second premolars have smaller teeth, there will be an increased challenge in closing the spaces left by extracted primary molars. We must ask the following questions. (1) Will treatment needlessly flatten the facial profile by closing the spaces if there is not profound crowding, especially if upper teeth are also extracted? (2) Will an overjet correction be more difficult to obtain, especially if we do not extract in the upper?

To answer these questions, the response of 23 consecutive patients treated by hemisection was compared with that experienced by patients treated with a variety of other options. These options include (1) one group treated with the extraction of four first premolars; (2) a separate group treated with the extraction of four second premolars; and (3) the changes that take place in the untreated Bolton sample between ages nine and 12 years.

## MATERIALS AND METHODS

All 23 hemisection cases were treated by the author. There were five Class I; 10 Class II, division 1; and eight Class II, division 2 patients included in the study. Ultimately, 12 patients had no teeth removed in the upper arch, which included four patients from each of the above three classifications. There was one Class I; six Class II, division 1; and four Class II, division 2 patients who did have teeth removed in the upper arch (five of these were congenitally missing upper teeth) (Table 1).

These 23 patients were compared with two groups of 30 patients (selected by discriminant analysis from a parent sample of 80), each having received four premolar extractions. Half of one group had the first premolars removed and the others had the second premolars removed. These 60 cases had been well treated by an excellent orthodontist in private practice and were described in the masters thesis of Komolpis.<sup>11</sup>

The pretreatment cephalometric measurements are presented in Table 1 with the data divided into the following

four groups. (1) Those from the Komolpis thesis<sup>11</sup> with four first premolars extracted; (2) Those from the Komolpis thesis with all four second premolars extracted; (3) Those who had hemisection and had no extractions in the maxilla; (4) Those that had hemisection and did have teeth removed in the maxilla.

All the hemisection cases were traced and measured manually by the author. Fifty per cent were traced twice for the purpose of performing an error study. Subsequently, each case was digitized using the Dentofacial Planner system. The Komolpis<sup>11</sup> data had been traced and digitized by Komolpis and verified by a faculty orthodontist. Our measurement technique was also reviewed by this same faculty orthodontist. The method used for comparison was the Pitchfork Analysis.<sup>12</sup> Accuracy was enhanced by repeating the analyses until consecutive drawings could be generated with less than a 0.1-mm discrepancy for each patient.

All models were measured by the author and a dental hygienist. The measurements were performed twice (at least one day apart) with a convertible Cen-Tech millimetric caliper, measuring in thousandths of millimeters. The procedure was fully explained to each patient, and their consent was obtained for their inclusion into this study. Analysis of variance was used for comparison (Table 2).

## Hemisection clinical protocol

Once the decision is made to remove the second primary molar (assuming the lower second premolar is missing), the tooth is cut in half and the distal half carefully removed. The procedure, in itself, is a beacon to avoid haphazard removal of the primary tooth that could result in the loss of the thin trabecula of bone between the permanent molar and the primary molar. And hopefully, the surgeon will not be inclined to "collapse" the alveolus around the site as was practiced.

The pulp is extirpated from the pulp chamber and calcium hydroxide (Dycal<sup>™</sup>) is placed to seal it off from contamination. Sometimes, it is helpful to place a small groove in the chamber floor to facilitate the seal. There is no need to provide endodontic extirpation to the remaining mesial root. The mesial portion almost always heals without negative consequences. The region can be observed as if it were a standard situation of sequential extraction.

When the permanent first molar drifts close enough to where further mesial migration becomes impeded, the mesial portion can be removed. At this point, it is prudent to be prepared to use some form of anchorage protection appliance to hold the lower anterior teeth forward. Such appliances could include an activator, a Jasper Jumper, perhaps a Herbst, protraction face mask, or a Hickham chin-cup. This could be combined with fully banded or bonded appliances for final space closure.

Panarex films and intraoral photos are provided for one

**TABLE 1.** Pretreatment Cephalometric Measurements for Five groups

	1st Bi	SD	2nd Bi	SD	Non-X	SD	Extract	SD	Unilateral	SD	P Value	Signifi- cance <sup>a</sup>
n	30		30		11		13		.10			
Mean age	13.03	1.4	13.98	4.45	10.45	2.21	9.26	0.91	9.03	1.37	<.001	**
Maxilla												
SNA	81.41	2.76	80.89	4.37	80.53	3.75	81.37	2.77	79.68	3.72	.8677	NS
Apt-N perp	1.88	3.27	1.62	0.36	0.09	3.56	1.72	2.26	-0.03	3.18	.3631	NS
Co-A pt	91.18	4.96	90.89	4.18	92.47	5.47	88.58	4.26	89.16	2.13	.2448	NS
Mandible												
SNB	77.3	3.36	78.04	3.67	77	3.36	76.21	3.61	75.17	4.11	.4871	NS
Po-N perp	-3.57	5.06	-0.47	4.77	-4.75	5.54	-5.89	5.14	-7.58	4.73	<.001	**
Po-NB	0.93	1.94	1.94	1.39	1.75	1.91	0.58	0.67	0.96	0.86	.0339	*
Md Unit L	114.75	6.69	115.75	4.74	116.27	7.65	108.62	4.25	109.32	3.65	.0063	**
Art-Gn	106.41	6.04	107.79	4.6	106.07	8.19	99.47	3.52	98.76	2.63	<.001	**
Intermaxillary												
ANB	4.1	1.86	2.83	1.73	3.53	2.28	5.16	1.81	4.51	2.37	.0037	**
A-B/Witts	-0.06	2.81	-0.25	1.87	0.05	2.95	-1.27	3.33	-1.96	2.46	.0572	NS
Vertical												
FMA	23.28	3.76	19.92	4.95	23	5.08	25.8	3.17	25.14	2.76	<.001	**
Y-axis	68.2	2.63	66.1	3.08	66.96	2.18	68.4	3.81	68.43	4.03	.0462	*
SN-PP	8.98	3.31	8.84	3.08	6.68	3.13	7.86	2.6	6.19	2.51	.1272	NS
SN-FOP	19.04	3.465	16.71	4.25	17.8	3.82	19.5	5.34	18.89	4.64	.1014	NS
N-ANS	52.36	3.3	52.85	3.54	50.37	4.09	49.19	1.33	48.41	3.2	.0075	**
ANS-Me	66.09	4.82	64.44	4.83	67.47	5.91	64.37	4.73	64.29	4.03	.2342	NS
N-Me	116.86	6.81	116	6.71	116.06	8.31	111.03	4.94	110.59	5.17	.1149	NS
Ar-Go	44.1	4.6	45.5	4.81	43.5	6.59	38.79	3.96	38.37	4.51	<.001	**
PFH:AFH	63.51	3.97	65.66	4.83	63.73	3.56	61.61	4.14	62.66	3.57	.0445	*
LFH:TFH	56.54	1.81	55.55	2.1	58.14	2.37	57.83	2.13	58.06	2.46	.0397	*
Up Dentition												
U1-SN	103.77	5.93	103.92	7.86	101.07	8.01	101.02	6.82	102.33	7.67	.4548	NS
U1-NA(°)	22.36	5.56	23.05	7.13	19.96	7.32	19.19	5.26	22.08	5.22	.2433	NS
U1-NA(mm)	3.76	2.15	4.38	2.51	3.13	2.69	1.88	1.56	2.52	1.58	.0222	*
Lo Dentition												
L1-NB g	24.95	5.29	22.93	5.28	23.28	5.25	24.25	5.5	23.52	5.12	.4864	NS
L1-NB mm	5.14	2.18	4.09	1.64	3.63	2.26	4.23	2.6	3.01	2.62	.1053	NS
L1/A-Pog	2	2.39	1.52	1.8	0.65	2.1	0.79	2.46	0.12	2.04	.1988	NS
FMIA	62.78	5.52	65.78	5.48	63.41	5.53	62.26	6.47	62.1	6.73	.1288	NS
IMPA	93.95	6.6	94.23	6.59	93.54	6.88	91.78	6.67	92.77	5.3	.7637	NS
U/L Relation												
UI/LI	128.59	7.77	131.16	9.69	133.35	8.99	130.81	6.83	129.51	6.75	.3807	NS
OJ (FOP)	4.94	1.95	4.64	1.11	4.64	1.82	4.77	2.08	5.46	1.92	.9058	NS
OB (FOP)	3.94	1.65	3.8	1.38	3.05	2.33	3.21	1.1	2.54	1.95	.2955	NS
Molar relation (FOP)	1.36	1.31	1.13	1.08	0.47	1.7	-0.51	1.99	-0.7	1.92	.0019	**
Soft Tissue												
Up Z angle	75.95	4.26	79.07	5.02	76.28	4.56	72.58	5.17	73.34	5.19	.0015	**
Lo Z angle	72.71	5.96	75.95	7.23	75.27	6.49	69.49	8.5	70.83	8.99	.0118	*
L lip-E plane	-0.05	2.42	-1.03	2.27	-1.61	3.05	0.25	2.74	-0.11	2.63	.1547	NS

<sup>a</sup> NS indicates nonsignificance; \*  $P < .05$ ; \*\*  $P < .01$ .

patient, DF (Figures 1 through 3). This case is especially instructive because, as a unilateral case, it clearly demonstrates the effectiveness of temporarily preserving the mesial half of the second primary molar. The response is representative of the type of anchorage preservation expected.

## RESULTS

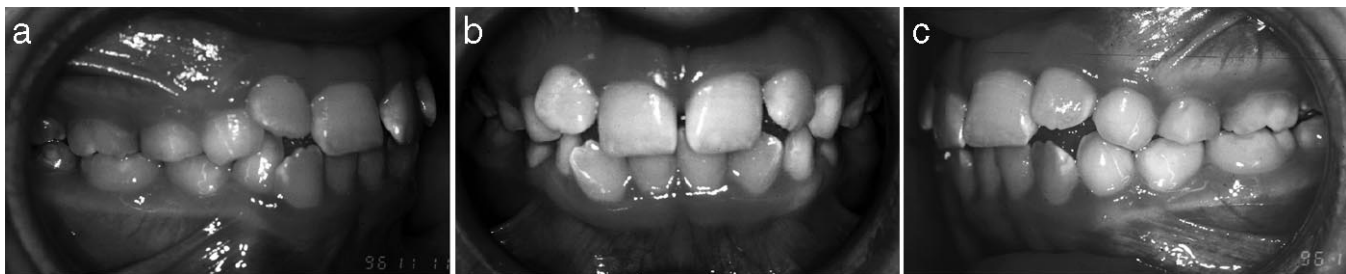### Treatment outcome

To evaluate treatment outcomes, especially as applied to anchorage loss, the Pitchfork Diagram<sup>1</sup> was used (Table 3). The groups compared are the two premolar extraction

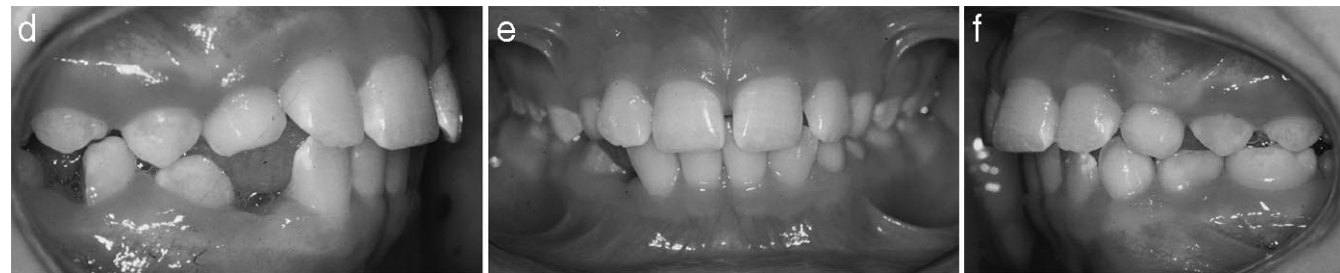**TABLE 2.** Dental Arch Dimensions

Variable	Lower 4's	Lower 5's	No Upper	Extract Upper	P Value	Significance
n	30	30	11	10		
3-3	32.61	32.32	31.00	30.11	<.01	**
$\overline{3-3}$	24.64	24.35	24.75	25.69	.085	NS
5-5	40.29	40.39	37.78	37.29	<.001	**
$\overline{5-5}$	35.23	34.94	36.55	35.57	.2216	NS
6-6	45.48	45.47	42.66	41.88	<.001	**
$\overline{6-6}$	40.87	40.68	42.64	41.36	.0831	NS
U arch depth	27.62	26.95	29.35	29.37	<.01	**
Lower	22.60	22.45	25.25	25.88	<.001	**
U discrepancy	-3.77	-2.85	+1.54	-2.44	<.001	**
Lower	-4.02	-3.07	+1.85	+1.00	<.001	**
Irregular index	7.21	6.67	3.77	4.27	<0.01	**

\*\*  $P < .01$ .



**FIGURE 1.** (a)–(c) Intraoral photographs of Patient DF apparent crowding with lower midline off 1–2 mm to right.



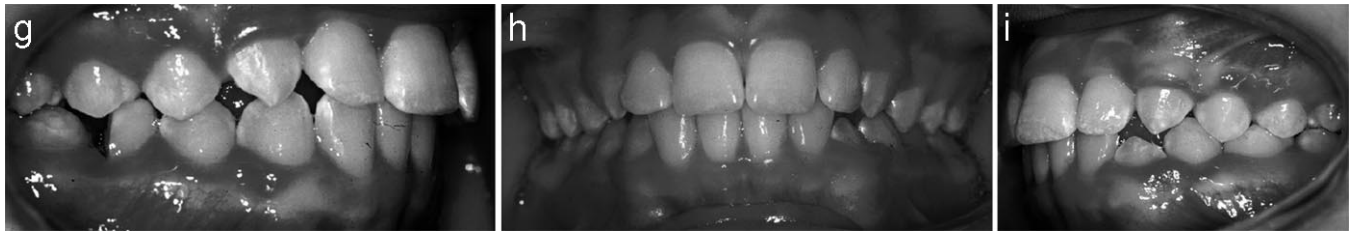**FIGURE 1.** (d)–(f) Four months after unilateral hemisection. Note the midline still off 1–2 mm.

groups, all the cases treated by hemisection, but not having teeth removed in the maxilla and all the cases being treated by hemisection, but having teeth removed in the maxilla and a control. To establish what might represent a nontreated control, the Bolton templates from ages nine and 12 years were measured and included in the table in this study.

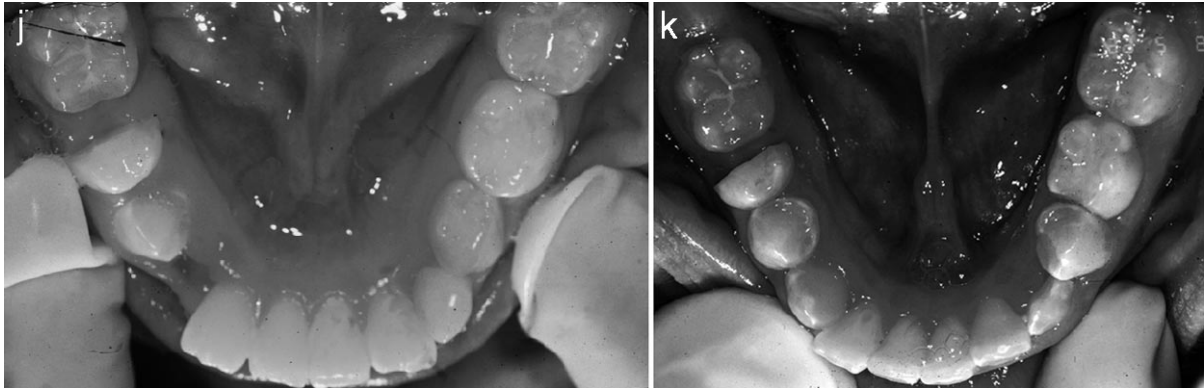
If we were to use conventional cephalometric measurements for comparison, the profound differences in the mean ages of the groups studied will predictably provide differences between T-1 and T-2 that would obscure the true treatment effect. Although it is conceded that age-related adjustments might have been made to the data,<sup>13</sup> this was not believed to be germane to this study. Accordingly, the measurement of maxillary change, mandibular change, and the apical base change are not judged to be relevant.

The total movement of the maxillary molar showed no

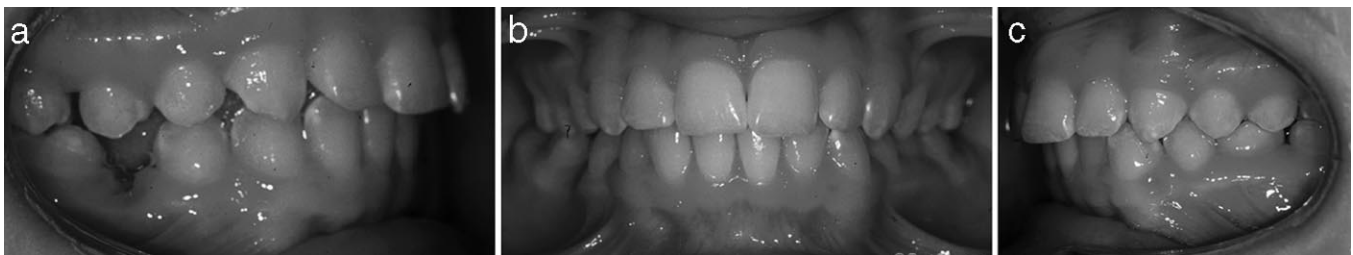statistically significant differences among the groups. However, the differences in movement of the lower molar were significant, with the hemisection groups showing much more protraction than the extraction groups (4.54 and 5.43 mm as opposed to 2.1 and 3.66 mm). Although the distal movement of the upper incisor (relative to the maxilla) was significantly greater for the extraction groups than those of the hemisection groups (2.21 mm for both of the extraction groups vs -1.1 mm for the nonextraction group and 0.04 mm for the upper extraction groups), there was no significant difference in movement of the lower incisor, relative to the mandible. It must be borne in mind that, according to the Pitchfork Analysis convention, movement that would move a Class II toward a Class I is registered as a positive, ie, backward movement of an upper molar or incisor is positive, whereas protraction would be measured as a negative.



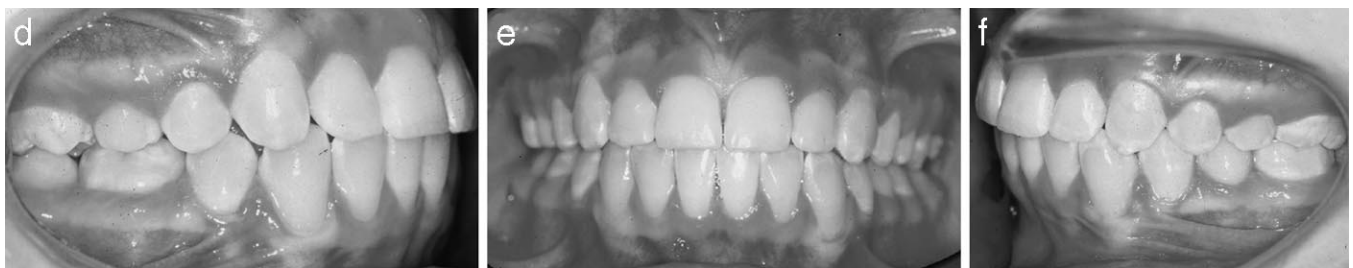**FIGURE 1.** (g)–(i) Seventeen months after hemisection. Space is nearly closed and ready for removal of the mesial half; midline is still unchanged.



**FIGURE 1.** (j) and (k) Mirror photos 4 months after hemisection and again at 17 months.



**FIGURE 2.** (a)–(c) Ready for fixed appliances; note that, only 8 months following the removal of the mesial “bookend,” the midline is beginning to shift toward the extraction.



**FIGURE 2.** (d)–(f) Following 13 months of braces, the midline has been easily restored and spaces are closed.

The net molar corrections were statistically significant with more molar relation correction for the hemisection cases than the premolar extraction groups. There were no statistically significant differences in overjet change.

The position of both upper and lower lip, relative to its respective jaw, showed statistically significantly different

amounts of change between the groups. The upper lip moved forward three mm on the Bolton template, 2.43 mm for those who had not upper teeth removed, 1.54 mm for the hemisection case who had upper teeth removed, and 0.36 or 0.11 mm, respectively, for those who had the first premolars or second premolars removed. The lower lip

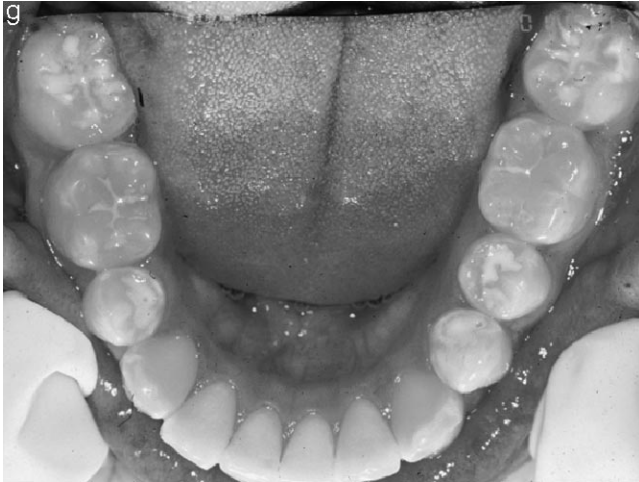

FIGURE 2. (g) Final mirror shot.

moved forward only in the hemisection group that had no upper teeth removed. The Bolton template showed a 0.2 mm retraction of the lower lip, the hemisection cases that had upper premolars removed had a 1.22-mm retraction and the premolar extraction cases experienced 2.44- and 1.61-mm retraction, respectively.

The treatment duration was 31.3 months in the lower first premolar extraction group, 28.5 months in the lower second premolar extraction group, 25.1 months in those cases treated by hemisection, and 32.2 months for the hemisection cases if you include first phase treatment. Statistics was not used to compare for significance.

### Arch dimensions

When the differences in pretreatment arch dimension were determined by measuring the dental casts, profound, statistically and clinically significant differences were found, especially when comparing the cases that had four premolars extracted with those in the hemisection group (Table 2). Nine of the 23 cases in the agenesis groups underwent maxillary expansion, and the maxillary widths were about 3.3 mm more narrow than those from the four-premolar extraction data. Arch length (depth) for the hemisection group was two to three mm longer, and circumference was similarly two to five mm longer in the maxilla and four to six mm in the mandible.

The index of irregularity was greater for those individuals in the Komolpis<sup>11</sup> data than those from the hemisection group. The measurement error for the dental casts was 0.33 and 0.28 mm for individual observers with an interobserver error of 0.32 mm.

### DISCUSSION

It is easy to decide to remove the primary molar in cases where there is crowding or where the teeth are extremely procumbent, cases that can afford anchorage loss. Although

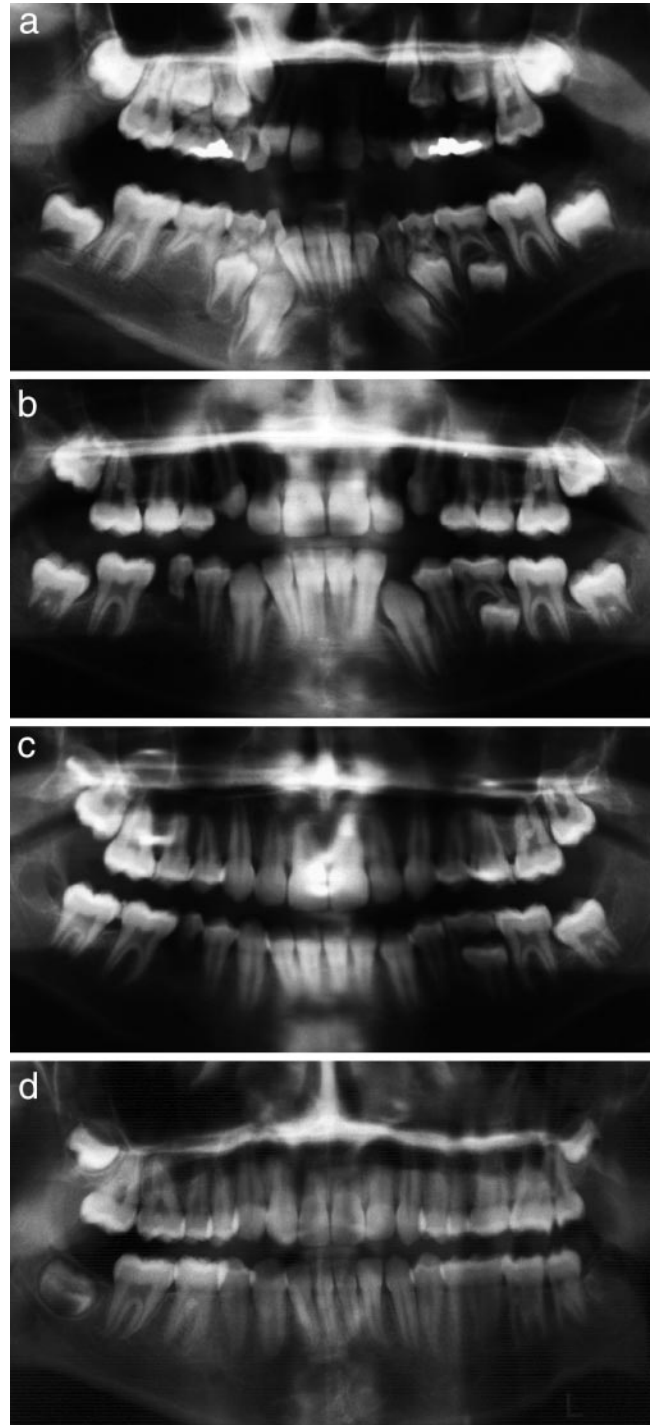


FIGURE 3. Panorex for Patient DF. (a) Note agenesis of lower right second premolar and inclination of lower incisors to drift to right. Note also the position of lower right canine (9-96); (b) In spite of hemisection performed 9-97, mesial portion has held interiors forward and space is closing by mesial drift of the molar (8-98); (c) Space continues to close while the midline is holding constant (see intraoral photographs); time to extract mesial half and initiate fixed appliances (8-99); (d) After 13 months of treatment the spaces are closed and anchorage had not been compromised (10-01).

**TABLE 3.** Pitchfork Measurements for Five Groups

	1st Bi	SD	2nd Bi	SD	Non-X	SD	Extract	SD	Bolton Series	P Value	Significance <sup>a</sup>
n	30		30		11		13				
Skeleton											
Maxilla	-1.33	1.66	-0.74	0.82	-2.89	2.15	-2.61	3.15	1.1	.0023	**
Mandible	3.59	2.78	2.2	2.09	6.64	6.52	6.33	4.1	3.3	.1019	NS
Apical base change	2.26	2.1	1.46	1.78	4.51	4.97	3.72	2.29	4.4	<.001	**
Dentition											
Upper											
U6 tip	-0.76	1.29	-0.67	1.27	-1.81	1.94	-1.78	0.92		.04101	*
U6 bodily	-2.35	1.55	-3.25	1.3	-1.56	1.99	-3.22	1.69		.0145	*
Total	-3.11	1.59	-3.92	1.46	-3.37	3.24	-4.9	1.96	-2.6	.09	NS
Lower											
L6 tip	-1.22	0.96	-0.95	1.05	-1.59	1.84	-1.24	1.46		.516	NS
L6 bodily	3.32	1.79	4.6	1.39	6.14	2.81	6.66	3.07		<.001	**
Total	2.1	1.53	3.66	1.04	4.54	2.89	5.43	2.32	0.2	<.001	**
U1 to maxilla	2.21	2.18	2.21	1.96	-1.1	3.14	0.04	2.24	-2.4	<.001	**
L1 to mandible	-2.13	2.62	-1.65	1.86	-2.2	2.77	-0.69	1.54	-1	.4496	NS
Total Correction											
Molar relation	1.26	1.51	1.18	1.07	5.68	3.45	4.42	2.98	0.7	<.001	**
Overjet relation	2.33	2.12	2.02	1.13	1.46	1.37	2.94	2.18	1	.3355	NS
Soft Tissue											
Upper lip	-0.36	1.81	-0.11	1.92	-2.43	3.8	-1.54	3.82	-3	.05	*
Lower lip	-2.44	1.97	-1.61	1.55	0.25	3.05	-1.22	2.62	-0.2	.0084	**

<sup>a</sup> NS indicates nonsignificance. \*  $P < .05$ ; \*\*  $P < .01$ .

this was not the case with the patients in this study, all patients finished treatment with spaces closed, dental discrepancies were not present in terms of interdigitation, and the profiles were not flattened.

The Pitchfork Analysis demonstrated the expected increase in lower molar protraction (necessary to close the space of the missing premolar) and the resulting improvement in molar relationship. The analysis also revealed the proficiency of the technique in preventing flattening of faces as revealed by two to three mm less retraction of the upper incisor than in the premolar extraction cases. This was only 1.5 mm less protraction than the Bolton sample experienced between age nine and 12 years. As measured at the upper lip, the effect was even more favorable. The upper lip in the nonextraction group failed to keep pace with the Bolton group by a mere 0.6 mm, whereas the premolar extraction groups experienced an additional four mm of retraction. The most surprising measurement was the lower lip, where the hemisection group outpaced the forward movement of the untreated Bolton group.

The differences in arch dimension shed light on the factors that favor a decision to extract and which tooth. There was much more crowding in the premolar extraction groups, two to three mm less arch depth, approximately five and six mm, respectively, less arch circumference for the upper and lower arches, and the index of irregularity showed two to four mm more crowding in the Komolpis<sup>11</sup> data. Only arch width measurements were smaller for the

hemisection cases than those of the extraction groups. Bear in mind that this was only the case for the maxillary dental widths, which were each about three mm narrower. This dearth of crowding in the hemisection cases makes the decision to have the primary molar removed and space closure even more challenging.

Mention should be made of the direction of "drift" that takes place in these cases. In every one of the cases where hemisection was initiated, there was a very positive mesial drift of the lower first molar, greatly aiding in the closure of space. Furthermore, in the aftermath of treatment, the teeth left distal to the first molar (second and third molars) consistently have responded with mesial migration, closing the remaining space. This is unlike the response found in the aftermath of mandibular second molar extraction, where drift seldom results in a closed contact point. Moreover, it is distinctly different from the distal migration that the second premolars (and even the first premolars) make when the lower first permanent molar is extracted before the eruption of the lower second molar. It is hoped that further investigation will shed light on the effect of timing, site specificity, and the multitude of factors (eg, the vertical pattern of facial growth) that influence space closure after extraction.

Hemisection is an extremely beneficial adjunct in the treatment of CML5, especially when the plan is to close the space left by agenesis in a case that would otherwise be treated as nonextraction. The alveolar contours appeared

normal at the end of treatment, spaces were closed, and there was a minimal facial flattening. Only minimal space closure takes place by distal movement of the teeth anterior to the hemisection site until the mesial half of the primary molar is removed. The technique enhances chances of avoiding the commensurate necessary extraction of upper premolars, enabling even less effect on facial profile during the space closure process.

### CONCLUSIONS

- Hemisection and removal of the distal half of the second primary molar, in cases where the lower second premolar is missing, provides an excellent first step in the process of space closure. This can be followed by removal of the mesial portion (the book-end) and space closure continued.
- The alveolar contour collapse that can take place during the extraction is minimized because of the increased care necessitated by the hemisection process, and the alveolus is not likely to atrophy in a smaller extraction site.
- With careful mechanics, the hemisection process can help to minimize the backward movement of the anterior teeth and diminish the flattening effect on facial profile that can occur with space closure.
- The advantage that hemisection can provide should induce the clinician to go the extra step and avoid extracting in the upper arch—even though the decision has been made to close the space in the lower. This will profoundly improve the quality of the result.

### ACKNOWLEDGMENTS

The author thanks Dr Frans van der Linden for ongoing mentoring since 1969 and for the suggestion to use the hemisection procedure. Appreciation is also rendered to Dr Lysle Johnston Jr, for providing the Komolpis thesis as well as assistance with statistics and the Pitchfork Analysis, and finally to John Meade who performed the statistics

and provided support and feedback. And thanks especially to my loving wife, Carin, who gives me the time to pursue my avocation in orthodontics and also measured the dental landmarks.

### REFERENCES

1. Garn SM. *Genetics of Dental Development. The Biology of Occlusal Development*. Monograph 7, Craniofacial Growth Series. Ann Arbor, Mich: University of Michigan; 1977:61–88.
2. Peck S, Peck L, Kataja M. Prevalence of tooth agenesis and peg-shaped maxillary lateral incisor associated with palatally displaced canine (PDCP) anomaly. *Am J Orthod Dentofacial Orthop*. 1996;110:441–443.
3. Baccetti T. A controlled study of associated dental anomalies. *Angle Orthod*. 1998;68(3):267–274.
4. Baccetti T. Tooth anomalies associated with failure of eruption of first and second molars. *Am J Orthod Dentofacial Orthop*. 2000;118(6):608–610.
5. Nodal M, Kjaer I, Solow B. Craniofacial morphology in patients with multiple congenitally missing teeth. *Eur J Orthod*. 1994;16:104–109.
6. Øgaard B, Krogstad O. Craniofacial structure and soft tissue profile in patients with severe hypoplasia. *Am J Orthod Dentofacial Orthop*. 1995;108:472–477.
7. Slavkin HC. *Genetics and the genome project: relevance to the practice of orthodontics in growth and treatment—a meeting of the minds*. McNamara, JA, Jr., Monograph 51, Craniofacial Growth Series. Ann Arbor, Mich: Department of Orthodontics and Pediatric Dentistry, Center for Human Growth and Development, University of Michigan. In press.
8. Markovic M. Hypodontia in twins. *Swed Dent J Suppl*. 1982;15:153–162.
9. van der Linden FPGM. *Development of the Dentition*. Chicago, Ill: Quintessence; 1983:72–73.
10. van der Linden FPGM. *Problems and Procedures in Dentofacial Orthopedics*. Chicago, Ill: Quintessence; 1990:289.
11. Komolpis RP. *Cephalometric Comparison between First Premolar and Second Premolar Extraction* [master's thesis]. Ann Arbor, Mich: University of Michigan; 1998.
12. Johnston L. Balancing the books on orthodontic treatment: an integrated analysis of change. *Br J Orthod*. 1996;23:93–102.
13. Johnston L. Growth and the Class II patient—rendering unto Caesar. *Semin Orthod*. 1998;4(1):59–62.